

## Kikuchi-Fujimoto disease—an unusual mimicker?

Diarmaid F Scully, Ceara Walsh, Hala F Eskander, David Kane

### Abstract

We describe the case of a 27-year-old Chinese female diagnosed with Kikuchi-Fujimoto disease in Ireland. It principally occurs in Asian populations, but is being increasingly reported in non-Asian populations. This rare, benign disease may potentially be misdiagnosed as lymphoma, and has an association with the subsequent development of systemic lupus erythematosus. Clinicians and pathologists need to be aware of the clinical and histological features of this rare disorder to avoid misdiagnosis.

### Case report

A 27-year-old female of Chinese descent was admitted for investigation of a 19-day history of intermittent fevers, cervical lymphadenopathy, anorexia, weight loss, pruritis, abnormal liver enzymes (ALT=1099, alkaline phosphatase=89, GGT=175, bilirubin=15), neutropaenia and thrombocytopaenia (WCC 2.4, neutrophils  $1.22 \times 10^9$ , lymphocytes  $1.01 \times 10^9$ ).

Multiple serological, immunological and autoimmune blood tests were completed as was a Mantoux test and liver ultrasound which were all normal. Her symptoms and lymphadenopathy began to resolve after 1 week with reduction in elevated liver enzymes. She was discharged with a suspected viral aetiology of unknown cause and a planned outpatient follow up.

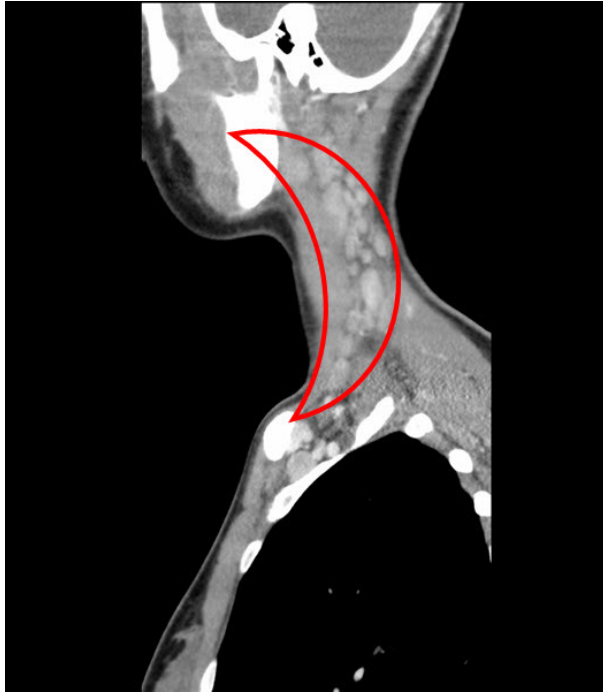She reattended 10 days later, with recurrent fevers, cervical lymphadenopathy and anorexia. In addition, she had developed nausea and vomiting. LDH was now noted to be 600 I/U. She remained febrile, and was initially managed with doxycycline, piperacillin/tazobactam and gentamicin.

CT neck, thorax, abdomen and pelvis demonstrated extensive left-sided cervical lymphadenopathy (Figure 1). A cervical lymph node biopsy was subsequently ordered, which was 5 days after her readmission.

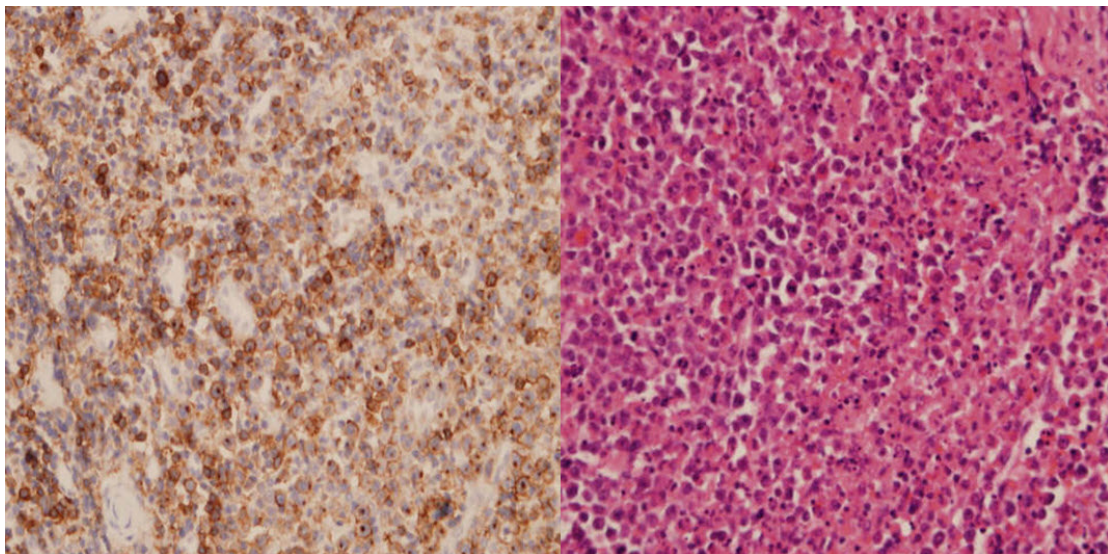
The preliminary verbal report was suspected lymphoma, however the official pathological report became available 3 days after she underwent the biopsy and demonstrated subacute necrotizing histiocytic lymphadenitis (Figure 2) confirming the result of Kikuchi-Fujimoto disease.

Ibuprofen was initiated and her symptoms started to resolve. She was discharged 1 week later (6 weeks, 1 day post first admission) with normal laboratory results and resolving symptoms. There were no clinical or laboratory abnormalities at review 3 months later and she is now being followed up yearly.

**Figure 1. Multiple enlarged lymph nodes in the posterior cervical triangle**



**Figure 2. In Kikuchi-Fujimoto disease, biopsies in the necrotizing phase show necrosis with abundant histiocytes but without a neutrophilic infiltrate. In this photomicrograph of a lymph node, we see areas of necrosis (pink area) and immunoblast in the periphery of the necrotic area (black dots). There are also a number of histiocytes containing apoptotic debris in this picture. On the right side, we see atypical lymphoid cells showing positive reactivity for CD8 which implies evidence for Kikuchi-Fujimoto disease**



## Discussion

Kikuchi-Fujimoto disease is a rare, benign, generally self-limiting disease of unknown cause, usually characterised by lymphadenopathy and fevers.

Lymphadenopathy is the most common symptom and is isolated to one region in approximately 83% of cases.<sup>1</sup> A flu-like prodrome has been reported in 30–50% of cases.<sup>2</sup> Other clinical and laboratory findings reported are rash (10%), arthritis (7%), hepatosplenomegaly (3%), leucopaenia (20–32%), elevated ESR (40%), anaemia (23%) and increased LDH suggesting hepatic involvement.<sup>3</sup>

Systemic symptoms are more likely with extra nodal involvement and include night sweats, nausea and vomiting, thoracic and abdominal pain, diarrhoea, weight loss, headache, rigors and myalgia.<sup>4</sup>

The potential for misdiagnosis of Kikuchi-Fujimoto disease as lymphoma or systemic lupus erythematosus (SLE) has been widely reported. In Dorfman and Berry's series, 40% of patients were initially diagnosed with malignant lymphoma and received chemotherapy of varying durations until Kikuchi-Fujimoto disease was finally diagnosed.<sup>5</sup> This may be due to the morphologic features being suspicious for lymphoma based on the florid immunoblastic proliferation and the presence of necrosis. It may also be due to its similar presentation to lymphoma.

Patients with Kikuchi-Fujimoto disease are at increased risk of subsequently developing SLE and need to be followed carefully. The only definitive diagnostic procedure is a lymph node biopsy (Figure 2).

Non-steroidal anti-inflammatory drugs (NSAIDs) are used for symptomatic relief of lymph node tenderness, fever and other pains. Corticosteroid use (50–60 mg po od) is recommended for severe extra nodal disease, hepatic and neurological involvement and severe lupus-like syndrome.<sup>6</sup>

Glucocorticoids with intravenous immunoglobulins have been used for persisting symptoms with apparent benefit.<sup>7</sup> Patients rarely suffer from recurrences of Kikuchi-Fujimoto disease (3%).<sup>8</sup> There has been one reported case of successful treatment of recurrent Kikuchi-Fujimoto disease with hydroxychloroquine.<sup>9</sup>

Kikuchi-Fujimoto disease was originally reported as a female predominant disease of Asian populations. The Census of 2006 reported that there were 354,552 Asians resident in New Zealand and clinicians practicing in New Zealand may rarely encounter this condition.

More recently it has been reported that Kikuchi-Fujimoto disease is not confined to the Asian population. In a review of 108 cases worldwide, 68 of these were reported in the United States<sup>2</sup> and a subsequent study by the same authors noted that 75% of 88 US patients with Kikuchi-Fujimoto disease were Caucasian.

Clinicians should consider Kikuchi-Fujimoto disease in the differential diagnosis of both Asian and non-Asian patients with unexplained lymphadenopathy and fevers.

**Author information:** Diarmaid F Scully, Senior House Officer, Dept of Rheumatology; Ceara Walsh, Specialist Registrar, Dept of Rheumatology; Hala F Eskander, Registrar, Dept of Pathology; David Kane, Professor of Rheumatology; AMiNCH, Tallaght, Dublin, Ireland

**Correspondence:** D Scully, Department of Rheumatology, Adelaide and Meath incorporating the National Children's Hospital, Tallaght, Dublin 24, Ireland. Email: [discully@tcd.ie](mailto:discully@tcd.ie)

**References:**

1. Kwon SY, Kim TK, Kim YS, et al. CT findings in Kikuchi disease: analysis of 96 cases. *AJNR Am J Neuroradiol.* Jun-Jul 2004;25(6):1099-102.
2. Dorfman RF, Berry GJ. Kikuchi's histiocytic necrotizing lymphadenitis: an analysis of 108 cases with emphasis on differential diagnosis. *Semin Diagn Pathol.* Nov 1988;5(4):329-45.
3. Kucukardali Y, Solmazgul E, Kunter E, et al. Kikuchi-Fujimoto Disease: analysis of 244 cases. *Clin Rheumatol* 2007;26:50.
4. Kuo, T. Cutaneous manifestation of Kikuchi's histiocytic necrotizing lymphadenitis. *Am J Surg Pathol* 1990;420:872.
5. Lin HC, Su CY, Huang CC, et al. Kikuchi's disease: A review and analysis of 61 cases. *Otolaryngol Head Neck Surg* 2003;128:650.
6. Jang YJ, Park KH, Seok HJ. Management of Kikuchi's disease using glucocorticoid. *J Laryngol Otol.* Sep 2000;114(9):709-11.
7. Lin DY, Villegas MS, Tan PL, et al. Severe Kikuchi's disease responsive to immune modulation. *Singapore Med J* 2010;51:e18.
8. Smith KG, Becker GJ, Busmanis I. Recurrent Kikuchi's disease. *Lancet* 1992;340:124.
9. Rezai K, Kuchipudi S, Chundi V, et al. Kikuchi-Fujimoto disease: hydroxychloroquine as a treatment. *Clin Infect Dis* 2004;39:e124.