

# Zoledronate-induced anterior uveitis, scleritis and optic neuritis: a case report

Laura E Wolpert, Andrew R Watts

**B**isphosphonates, such as zoledronate, are used by approximately 55,000 people per year in New Zealand<sup>1</sup> to prevent the loss of bone density in a range of conditions such as osteoporosis, Paget's disease of the bone and bone metastases.<sup>2</sup> Although ocular side effects are rare, bisphosphonates have been associated with acute anterior uveitis (AAU)<sup>3,4</sup> and scleritis.<sup>4,5</sup> There have also been case reports of optic neuritis following bisphosphonate use.<sup>6-8</sup> Here we report a case of a patient who progressively developed AAU, scleritis and optic neuritis following a zoledronate infusion.

## Case report

A 61-year-old woman with a past medical history of previous morbid obesity with sleeve gastrectomy, severe reflux and ileostomy secondary to hemicolectomy for severe diverticular disease presented to the eye clinic with a three-day history of right eye pain, photophobia and blurred vision. These symptoms commenced one day following her first zoledronate infusion for osteoporosis. She had no significant past ophthalmic history.

Right eye visual acuity was 6/15 and left eye visual acuity was 6/9. Intraocular pressures were normal. She had right circumlimbal injection with cells and flare in the anterior chamber. Fundal examination was normal. An initial diagnosis of AAU was made and treatment with prednisolone 1% eye drops and cyclopentolate 1% eye drops was commenced.

Two days later the patient presented with worsening pain and vision and pain on eye movements. Right visual acuity had decreased to 6/24. She had red desaturation

with proptosis, periorbital oedema, conjunctival chemosis and injection and cells and flare in the anterior chamber (Figure 1A). There was no evidence of vitritis, and fundal examination was normal.

A B-scan of the right eye showed scleral thickening (Figure 2). The patient underwent a CT scan of her orbits, which revealed right-sided proptosis with intraconal fat stranding and inflammation surrounding the globe and optic nerve, consistent with scleritis and retrobulbar optic neuritis (Figure 3). Investigations, including serum ACE, treponemal serology, ANA and QuantiFERON-TB Gold, were unremarkable.

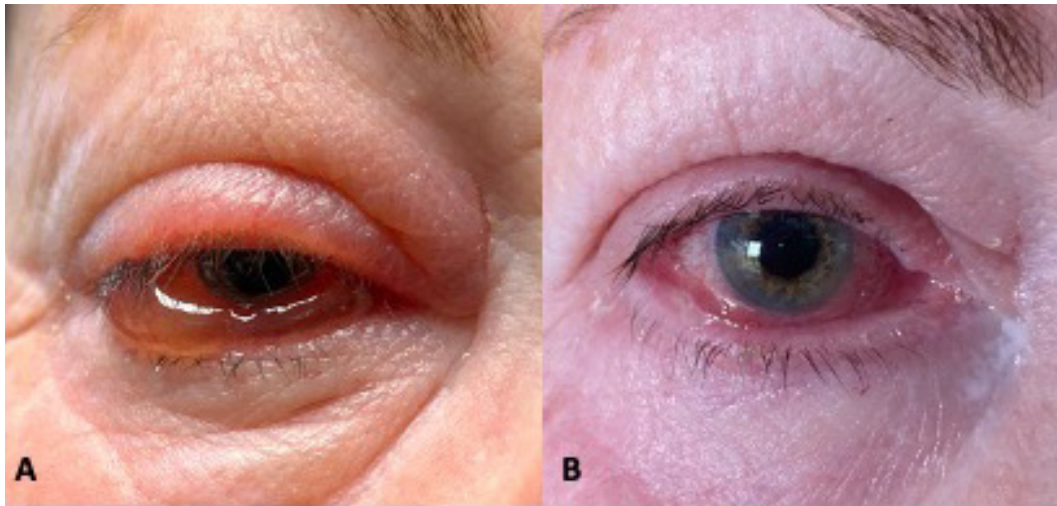
A diagnosis of zoledronate-induced uveitis, scleritis and optic neuritis was made. The patient received 1g intravenous methylprednisolone, which resulted in a rapid improvement of her symptoms and signs by the following day (Figure 1B). The patient was then discharged on a weaning course of oral prednisone, topical prednisolone 1% eye drops and cyclopentolate 1% eye drops. At one week follow-up the inflammation had resolved.

## Discussion

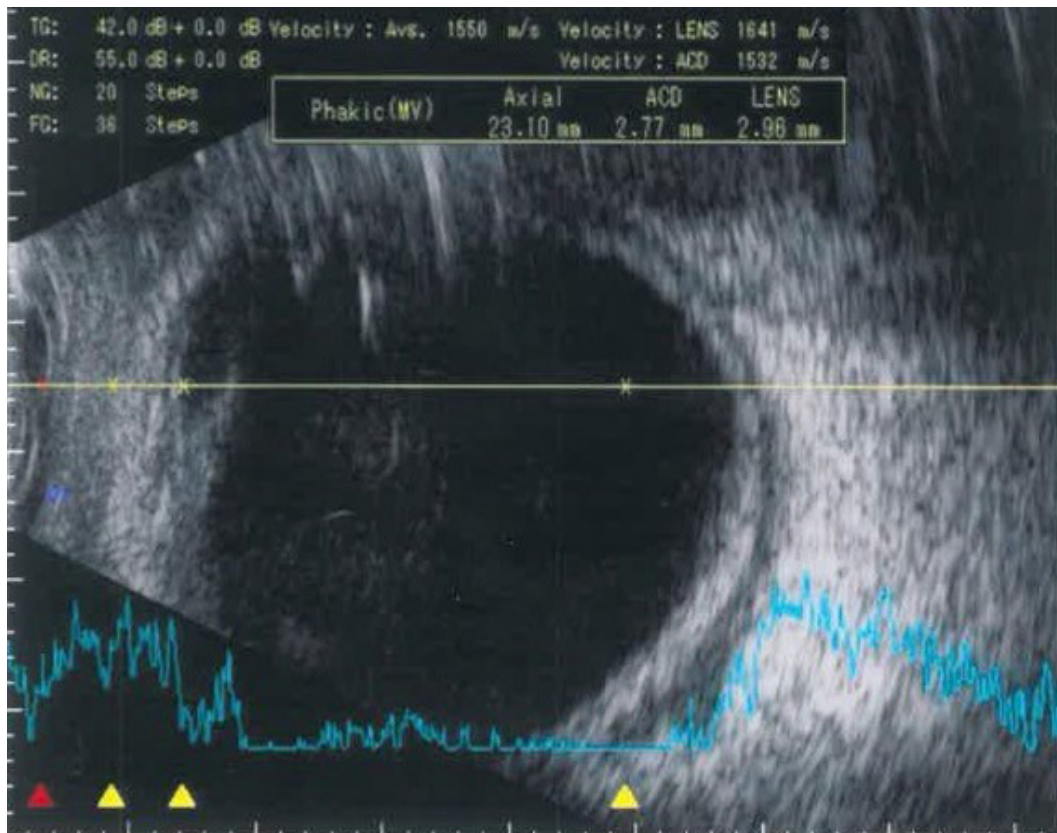
Orbital inflammation is an uncommon side effect of zoledronate infusion. The incidence of zoledronate-associated AAU has been reported at around 1.1%.<sup>3</sup> To our knowledge, there are only two case reports of zoledronate-associated optic neuritis,<sup>7,8</sup> although optic neuritis has been seen with other bisphosphonates in a few cases.<sup>6</sup>

There is little information on bisphosphonate rechallenge following adverse ocular events. Adverse ocular events have been reported following bisphosphonate

**Figure 1:** (A) The patient's right eye five days following a zoledronate infusion, showing proptosis, lid oedema and conjunctival chemosis. (B) The patient's right eye after treatment with intravenous methylprednisolone, which resulted in reduced peri-ocular swelling and chemosis. The pupil is dilated due to cyclopentolate drops.



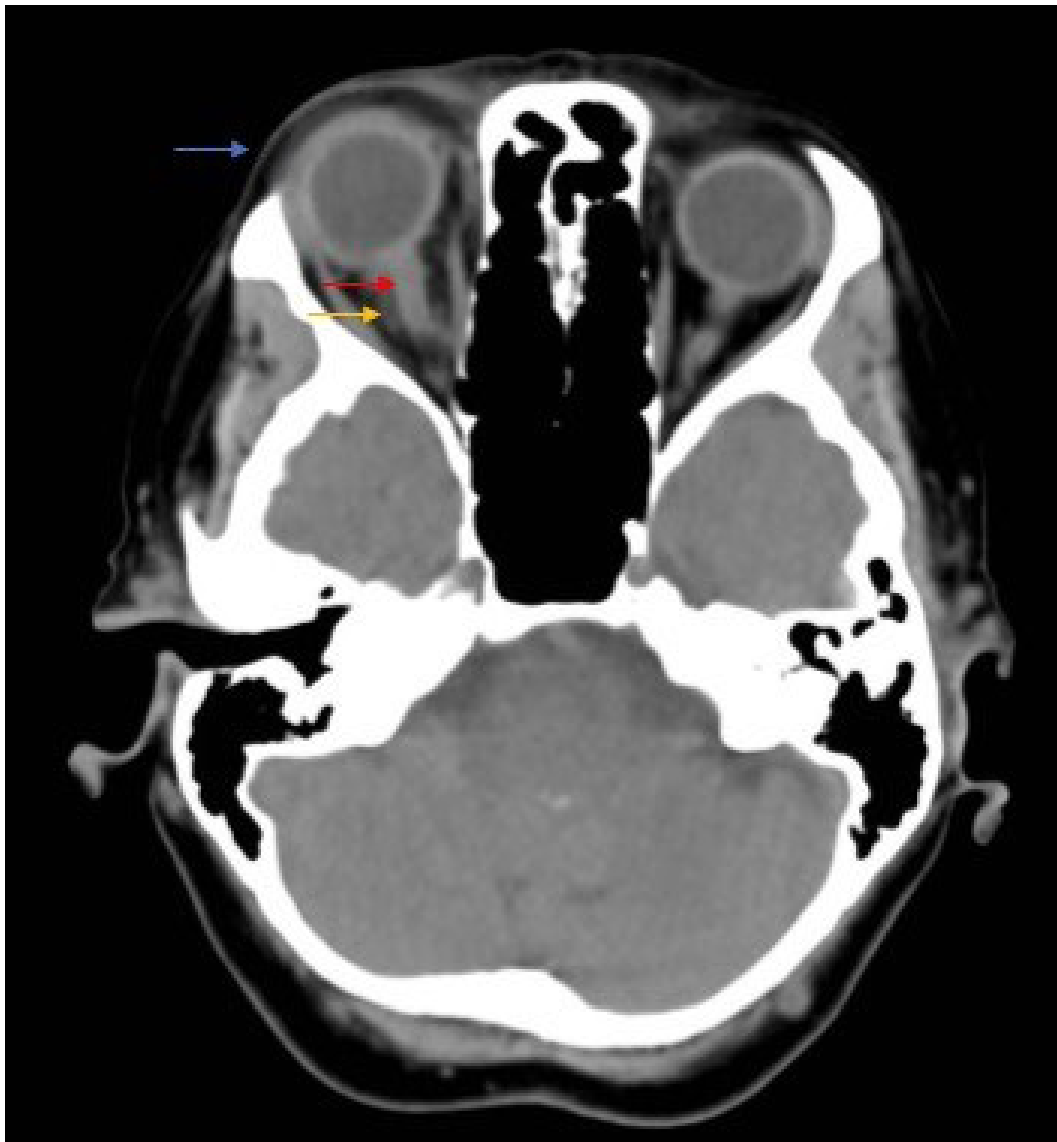**Figure 2:** A B-scan of the patient's right eye showing scleral thickening (white arrow).



rechallenge but do not occur in all cases.<sup>9,5-7</sup> Although inflammation associated with bisphosphonate use is usually mild and shows complete resolution after cessation of the precipitating agent and treatment of the ocular inflammation, in the context of potentially sight-threatening conditions such as scleritis and optic neuritis, rechallenge may not be advisable.

Recognition of drug-induced ocular inflammation is critical to allow for prompt referral to an ophthalmologist and withdrawal of the drug in question. Patients receiving bisphosphonate treatment should be counselled to seek medical attention if they develop symptoms of visual loss, eye pain or eye redness.

**Figure 3:** CT scan showing right eye proptosis (blue arrow), intraconal fat stranding (yellow arrow) and optic nerve thickening (red arrow).



**Competing interests:**

Nil.

**Author information:**

Laura E Wolpert: Ophthalmology Registrar, Department of Ophthalmology, Whangarei Hospital, Northland District Health Board, Maunu Road, Whangārei 0148, New Zealand.

Andrew R Watts: Consultant Ophthalmologist, Department of Ophthalmology, Whangarei Hospital, Northland District Health Board, Maunu Road, Whangārei 0148, New Zealand.

**Corresponding author:**

Dr Laura Wolpert, Department of Ophthalmology, Whangarei Hospital, Northland District Health Board, Maunu Road, Whangārei 0148, New Zealand, 09 430 4100  
laura@wolperts.com

**URL:**

[www.nzma.org.nz/journal-articles/zoledronate-induced-anterior-uveitis-scleritis-and-optic-neuritis-a-case-report](http://www.nzma.org.nz/journal-articles/zoledronate-induced-anterior-uveitis-scleritis-and-optic-neuritis-a-case-report)

**REFERENCES**

1. Best Practice Advocacy Centre New Zealand [Internet]. An update on bisphosphonates. Accessed Jan, 2021. Available from: [www.bpac.org.nz](http://www.bpac.org.nz)
2. Drake MT, Clarke BL, Khosla S. Bisphosphonates: mechanism of action and role in clinical practice. *Mayo Clin Proc.* Sep 2008;83(9):1032-45. doi:10.4065/83.9.1032
3. Patel DV, Bolland M, Nisa Z, et al. Incidence of ocular side effects with intravenous zoledronate: secondary analysis of a randomized controlled trial. *Osteoporos Int.* Feb 2015;26(2):499-503. doi:10.1007/s00198-014-2872-5
4. Keren S, Leibovitch I, Ben Cnaan R, et al. Aminobisphosphonate-associated orbital and ocular inflammatory disease. *Acta Ophthalmol.* Aug 2019;97(5):e792-e799. doi:10.1111/aos.14063
5. Samalia P, Sims J, Niederer R. Drug-induced ocular inflammation. *N Z Med J.* Dec 2020;133(1527):83-94.
6. Stack R, Tarr K. Drug-induced optic neuritis and uveitis secondary to bisphosphonates. *N Z Med J.* Mar 2006;119(1230):U1888.
7. Brulinski P, Nikapota AD. Zoledronic acid-induced retrobulbar optic neuritis: a case report. *Clin Oncol (R Coll Radiol).* May 2013;25(5):328-9. doi:10.1016/j.clon.2012.12.006
8. Lavado FM, Prieto MP, Osorio MRR, Gálvez MIL, Leal LM. Bilateral retrobulbar optic neuropathy as the only sign of zoledronic acid toxicity. *J Clin Neurosci.* Oct 2017;44:243-5. doi:10.1016/j.jocn.2017.06.048
9. Patel DV, Horne A, Mihov B, Stewart A, Reid IR, McGhee CN. The Effects of Re-challenge in Patients with a History of Acute Anterior Uveitis Following Intravenous Zoledronate. *Calcif Tissue Int.* Jul 2015;97(1):58-61. doi:10.1007/s00223-015-0015-4