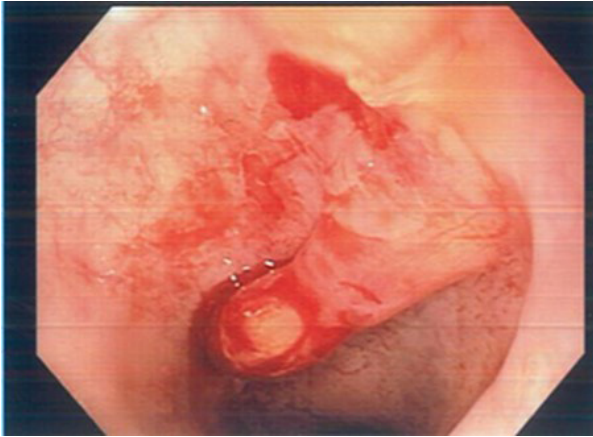
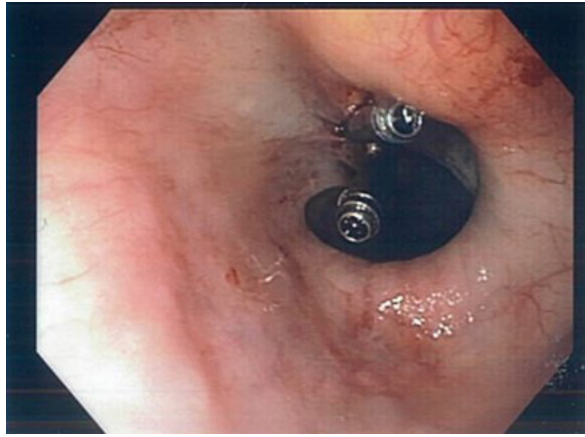


**Figure 1:** Endoscopic visualisation of oesophageal lipoma.



**Figure 2:** Mucosal defect post-resection closed with endoclips.



**Figure 3:** Post-procedure barium swallow; endoclips are seen with no evidence of leak identified.

