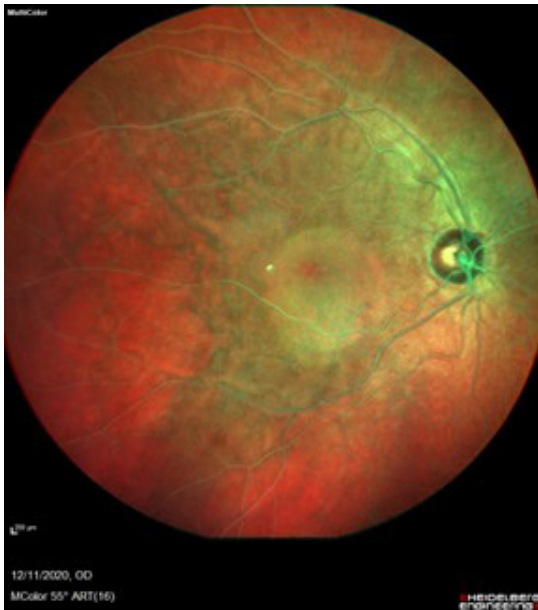

Figure 1: Colour fundus photography of the right (a) and left eye (b) showing CME.

a.

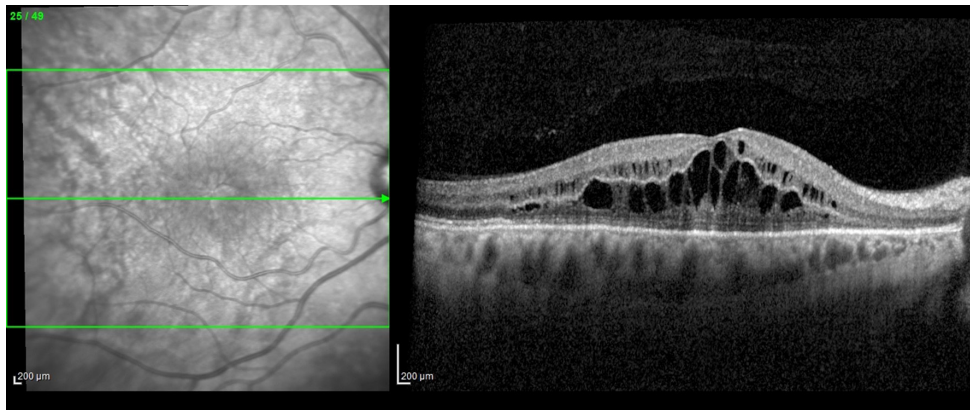


b.

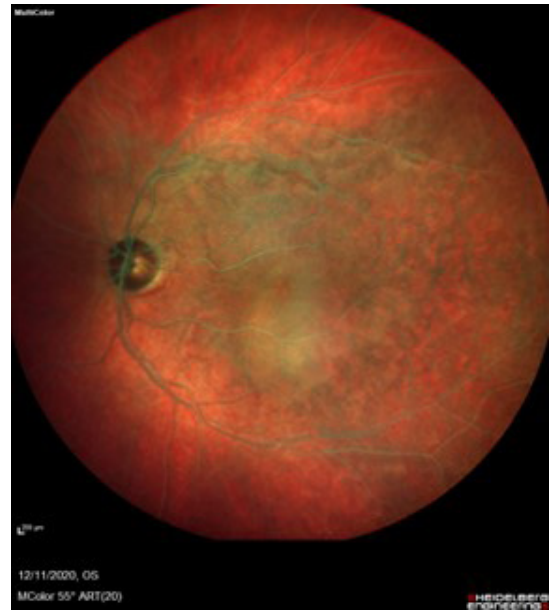

Figure 2: Spectral-domain optical coherence tomography of the right (a) and left eye (b) showing CME with intra-retinal fluid in the outer plexiform layer and cystoid changes in the inner retinal layer.

a.



b.

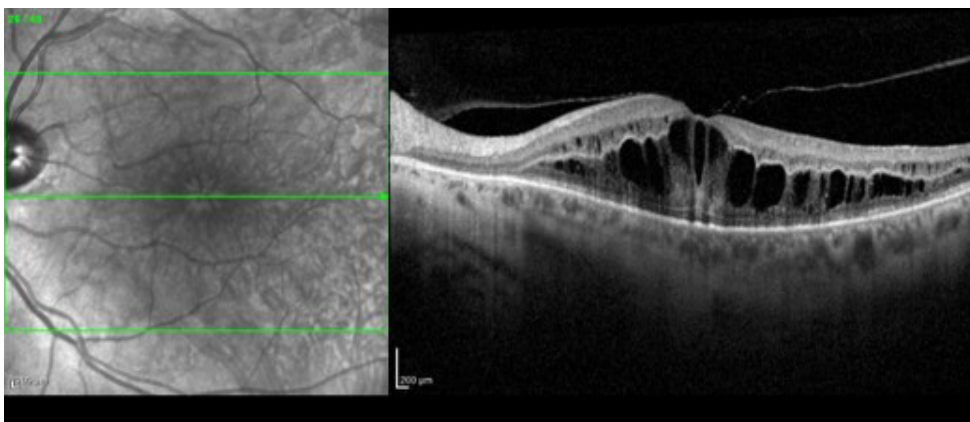


Figure 3: Fluorescein angiography showed bilateral CME with no leakage or increasing hyperfluorescence in the late phase.

