

Figure 1: CT scan showing thickened anterior pericardium approximately 5.5mm in thickness.

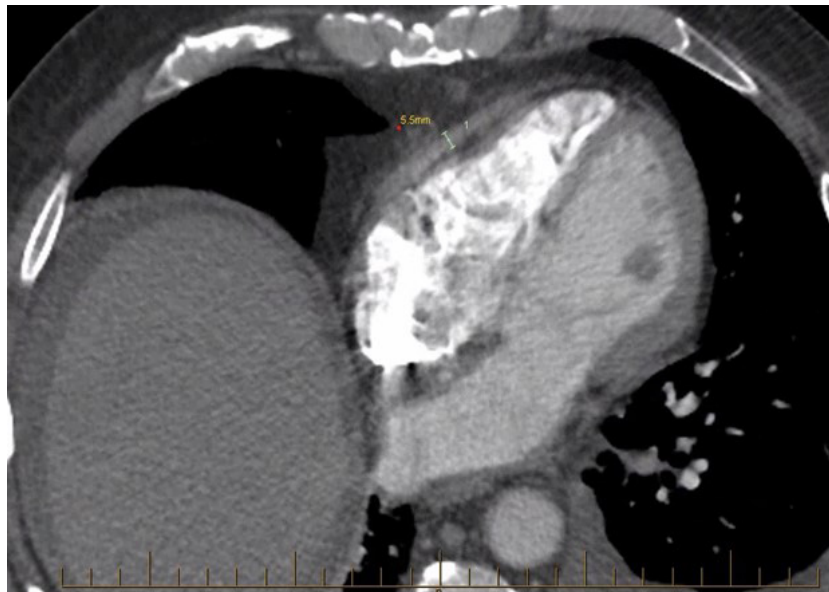


Figure 2: Intra-operative images. Enhanced to increase visualisation of stiffened anterior pericardium (dotted line). Arrow showing resected pericardium.

