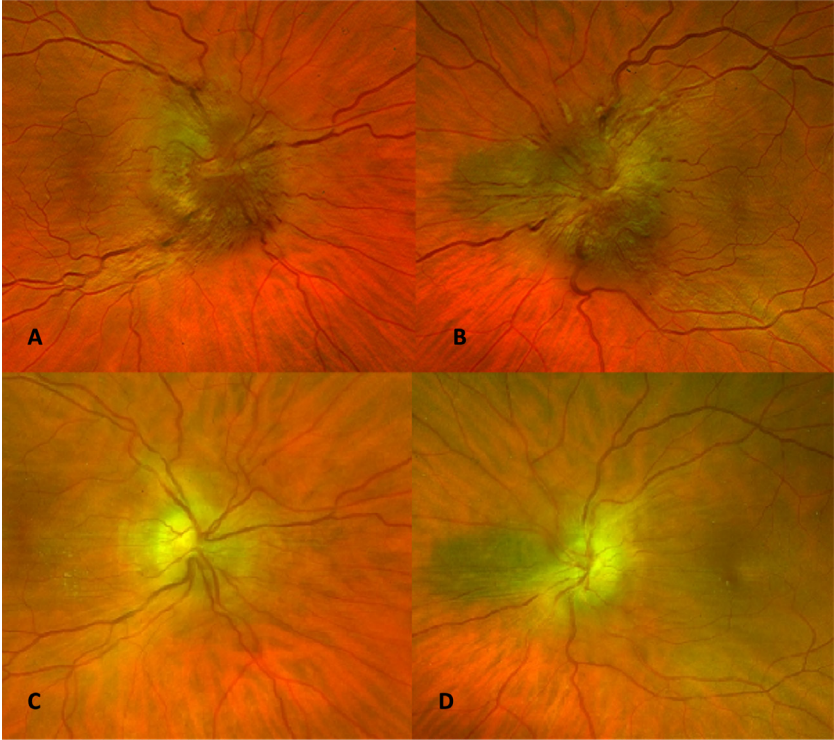


**Figure 1:** Pseudo-colour images of the left and right optic discs (right and left respectively). A/B—appearance of discs at presentation. C/D—appearance of discs after ventriculo-peritoneal (VP) shunt placement.



**Figure 2:** T2-weighted magnetic resonance venogram (MRV) of the brain with Gadolinium contrast demonstrating thrombus in the left transverse sinus, denoted by the green arrow.

