

Figure 1: Colonoscopy view of the terminal ileum.

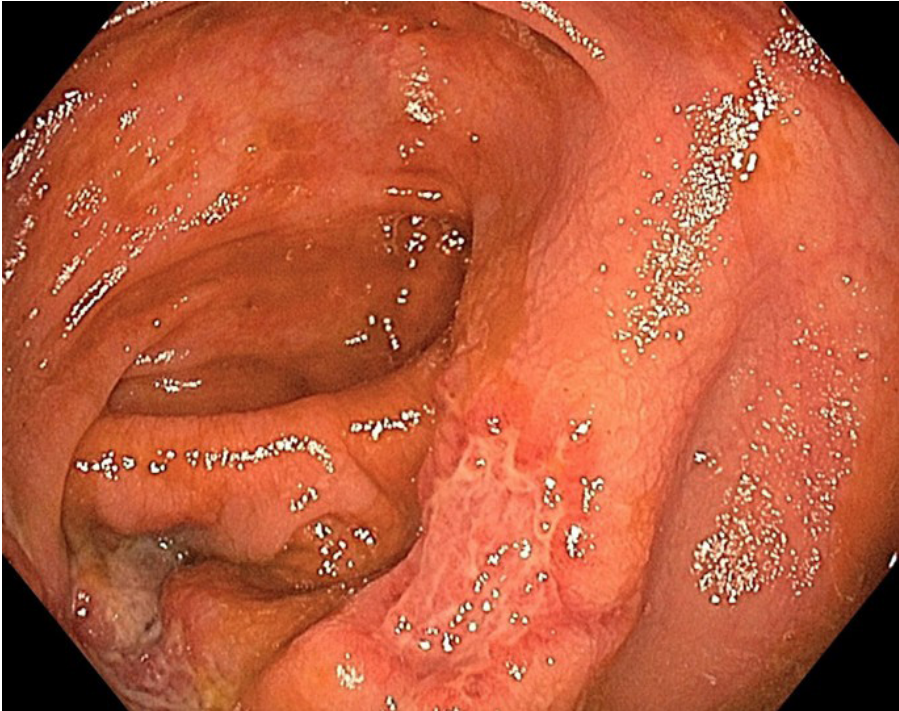


Figure 2: Histopathology of terminal ileum biopsies.

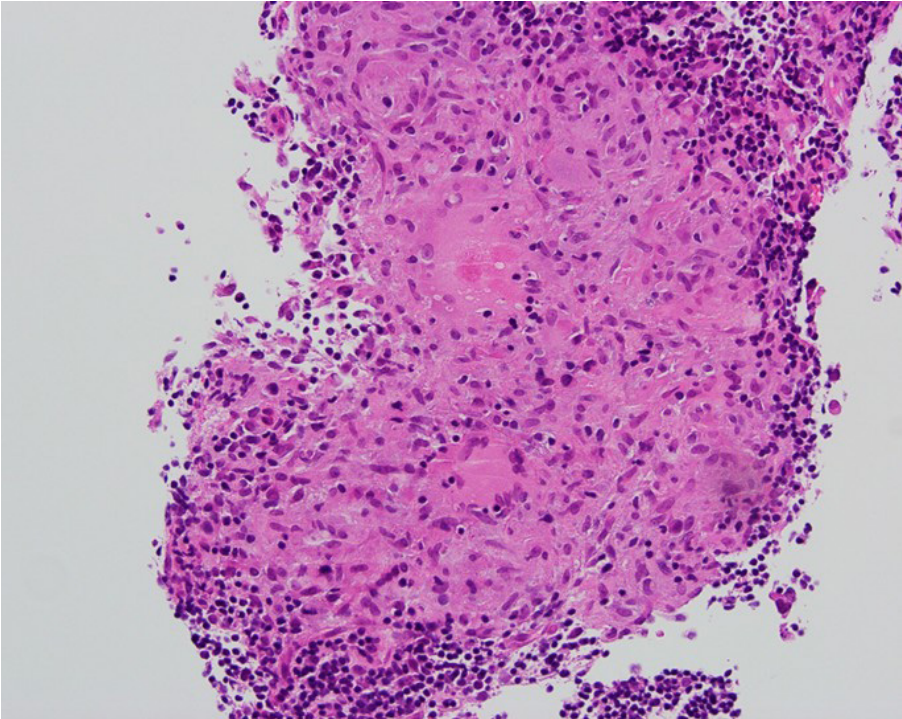


Figure 3: Magnetic resonance enterography.

