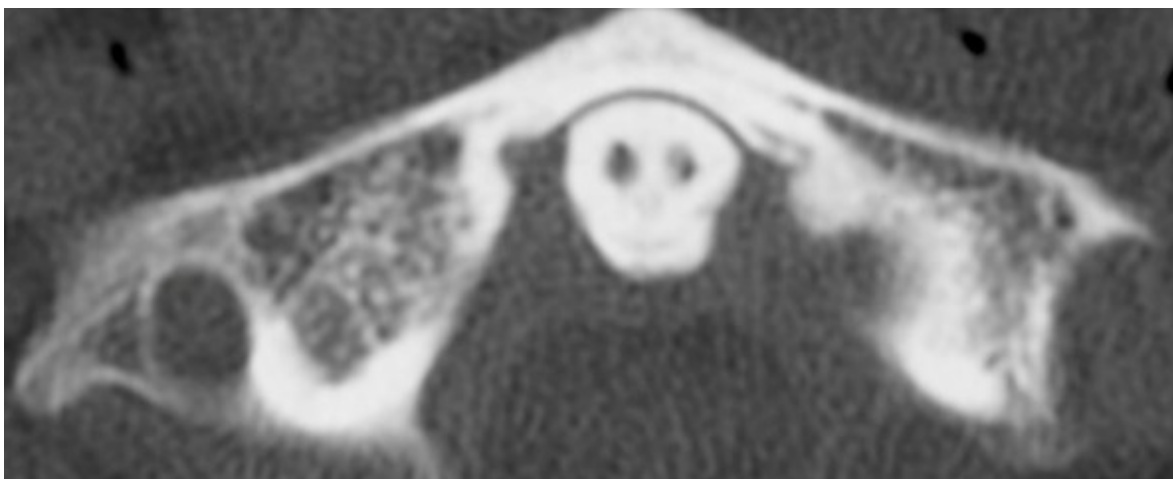

# Grim findings: when the Reaper haunts the radiograph

Stephen Rowlands

**Figure 1:** Grim Reaper appearance within radiograph of atlas bone of the neck.



**T**his article explores the rare—and entirely incidental—appearance of a Grim Reaper-like figure within a radiograph, highlighting the fascinating intersection of medical imaging and the tricks of human perception such as the psychological phenomenon of pareidolia. As part of a trauma scan following a road traffic accident, a rather chilling silhouette emerged from within the trabecular of an odontoid process. Despite the funereal appearance, no harm was caused by the accident and the patient was discharged home.

Pareidolia is the tendency to perceive recognisable patterns, such as faces or figures, in complex stimuli.<sup>1</sup> In radiology, pareidolia may aid in pattern recognition but can also contribute to diagnostic pitfalls, such as over-reading or under-reading findings based on subconscious visual biases.

The human brain's tendency for facial and figure recognition is evolutionarily advantageous but can yield humorous or eerie interpretations. Cases of pareidolia in medicine are rare but not unprecedented, with reported examples including the Star Wars “Baby Yoda” character being seen in sacral magnetic resonance imaging

and computed tomography scans.<sup>2</sup>

The “Grim Reaper” observed in this case did not influence patient management but can serve as a teaching example.

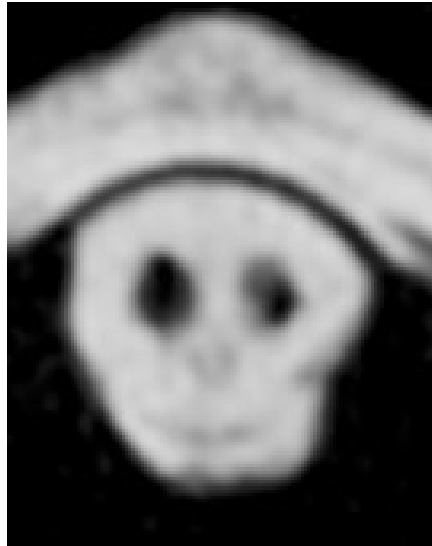
The odontoid is a protuberance of the axis, which articulates with the anterior arch of the atlas, forming a pivot joint. Degenerative changes of the periarticular odontoid can sometimes appear as a cluster of cysts, in this case resembling that of a gothic skull.<sup>3</sup> These types of bone cysts often develop in areas of focal bone pressure.<sup>4</sup> Despite this patient having no acute injury, these cysts can indeed increase the risk of cervical injury after relatively minor trauma, and those with odontoid fractures are nearly eightfold more likely to have an interosseous cyst.<sup>5</sup>

This case highlights how pareidolia can arise in medical imaging, producing striking but incidental appearances such as the Grim Reaper-like silhouette seen within the odontoid process. While such findings are visually compelling, they carry no diagnostic significance and should not distract from accurate interpretation. Awareness of pareidolia is important for radiologists and clinicians alike, as it underscores the influence of subconscious visual biases on image

reading. At the same time, these cases offer unique opportunities for teaching, both to reinforce anatomical knowledge, such as the structural

and pathological features of the odontoid, and to illustrate the cognitive pitfalls that can affect radiologic practice.

**Figure 2:** Zoomed-in Grim Reaper appearance within radiograph of atlas bone.



---

**COMPETING INTERESTS**

Nil.

**CORRESPONDING AUTHOR INFORMATION**

Stephen Rowlands: Surgical Registrar, Wellington  
Regional Hospital, New Zealand.  
E: stephenrowlands@live.com

**URL**

[https://nzmj.org.nz/journal/vol-139-no-1629/  
grim-findings-when-the-reaper-haunts-the-radiograph](https://nzmj.org.nz/journal/vol-139-no-1629/grim-findings-when-the-reaper-haunts-the-radiograph)

**REFERENCES**

1. Liu J, Li J, Feng L, et al. Seeing Jesus in toast: neural and behavioral correlates of face pareidolia. *Cortex*. 2014 Apr;53:60-77. doi: 10.1016/j.cortex.2014.01.013.
2. Foye PM, Koger TJ, Massey HR. Baby Yoda: Pareidolia and Patternicity in Sacral MRI and CT Scans. *PM R*. 2021 Nov 9;13(2):217-218. doi: 10.1002/pmrj.12496.
3. Daniels AH. Ghost-face cystic degeneration pattern of the odontoid process. *The Spine Journal*. 2012 Dec 21;13(2):202-203.
4. Bancroft LW, Peterson JJ, Kransdorf MJ. Cysts, geodes, and erosions. *Radiol Clin North Am*. 2004 Jan;42(1):73-87. doi: 10.1016/S0033-8389(03)00165-9.
5. Julien TP, Schoenfeld AJ, Barlow B, Harris MB. Subchondral cysts of the atlantoaxial joint: a risk factor for odontoid fractures in the elderly. *Spine J*. 2009 Jun 17;9(10):e1-4. doi: 10.1016/j.spinee.2009.04.025.