

Figure 1: Sagittal and coronal views detailing appendix passing into hernia—de Garengeot hernia.

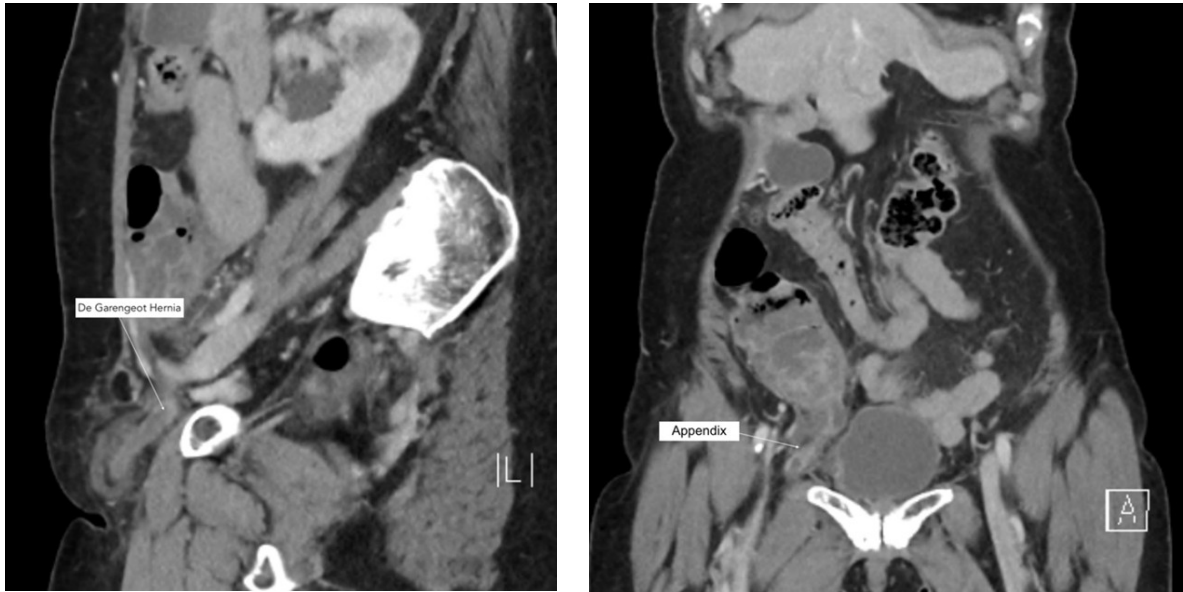


Figure 2: Relevant anatomy.

