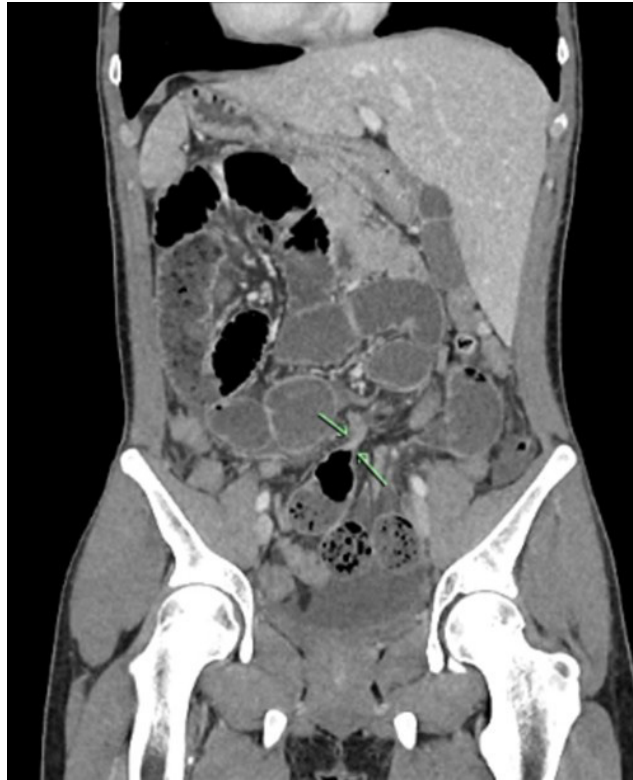
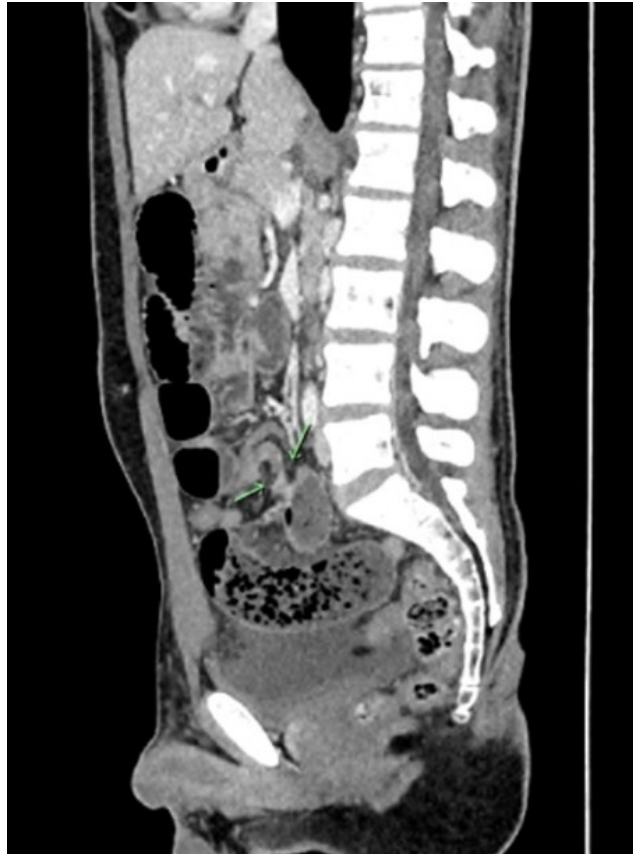
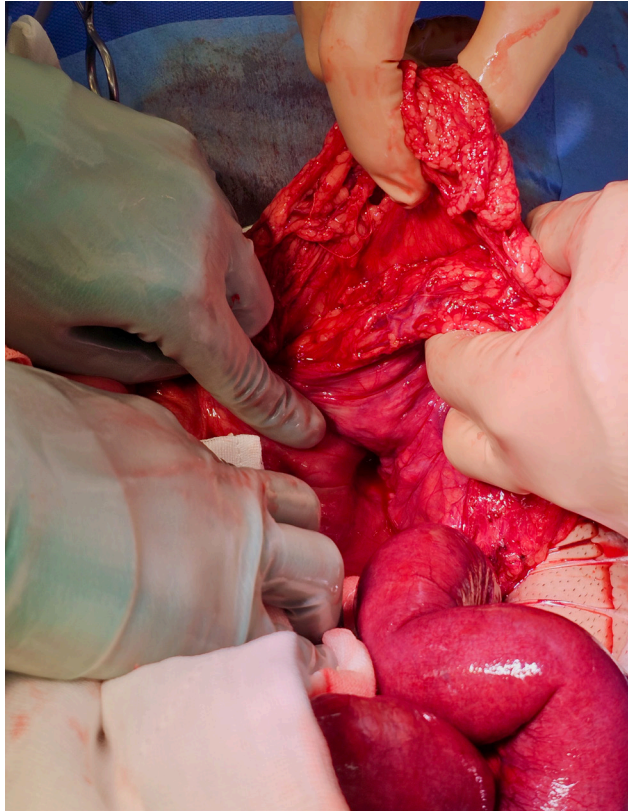
**Figure 1:** Key image from contrast enhanced computed tomography (CT) scan.



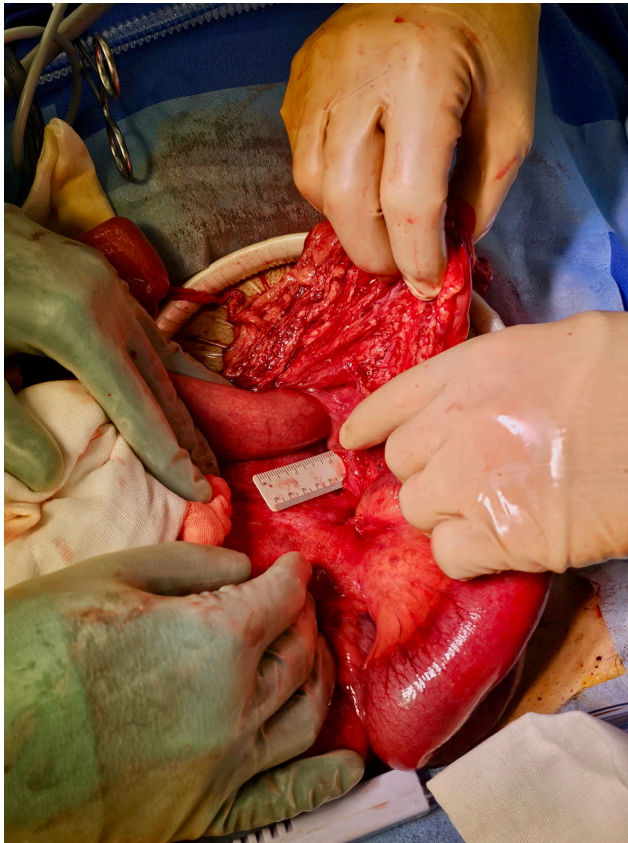**Figure 2:** Key image from contrast enhanced computed tomography (CT) scan.



**Figure 3:** Defect with left colic artery.



**Figure 4:** Extent of defect extending up to 10cm.



**Figure 5:** Thickened peritoneum of hernia sac.

